

Evidence-Based Recommendations for Local Antimicrobial Strategies and Dead Space Management in Fracture-Related Infection

Willem-Jan Metsemakers, MD, PhD,* Austin T. Fragomen, MD,† T. Fintan Moriarty, PhD,‡

Mario Morgenstern, MD,§ Kenneth A. Egol, MD,|| Charalampos Zalavras, MD, PhD,¶

William T. Obrebsky, MD, MPH,** Michael Raschke, MD, PhD,††

and Martin A. McNally, MD, FRCS(Orth)‡‡ on behalf of the Fracture-Related Infection (FRI) consensus group

Summary: Fracture-related infection (FRI) remains a challenging complication that imposes a heavy burden on orthopaedic trauma patients. The surgical management eradicates the local infectious focus and if necessary facilitates bone healing. Treatment success is associated with debridement of all dead and poorly vascularized tissue. However, debridement is often associated with the formation of a dead space, which provides an ideal environment for bacteria and is a potential site for recurrent infection. Dead space management is therefore of critical importance. For this reason, the use of locally delivered antimicrobials has gained attention not only for local antimicrobial activity but also for dead space management. Local antimicrobial therapy has been widely studied in periprosthetic joint infection, without addressing the specific problems of FRI. Furthermore, the literature presents a wide array of methods and guidelines with respect to the use of

local antimicrobials. The present review describes the scientific evidence related to dead space management with a focus on the currently available local antimicrobial strategies in the management of FRI.

Key Words: local antimicrobials, local antibiotics, fracture-related infection, dead space management, debridement, irrigation, PMMA, osteomyelitis, ceramics, carriers, fracture, infection

Level of Evidence: Therapeutic Level V. See Instructions for Authors for a complete description of levels of evidence.

(*J Orthop Trauma* 2020;34:18–29)

INTRODUCTION

Fracture-related infection (FRI) remains a challenging complication. Surgical management is often unavoidable, particularly for chronic/late onset infections where osteolysis and biofilm formation are generally present. Successful eradication of infection requires debridement of affected tissues, removal of loose implants or foreign bodies, creation of a stable fracture environment, dead space management, and systemic antimicrobial therapy. Administration of local antimicrobials, in addition to systemic therapy, may be beneficial.^{1,2}

The adjunctive application of local antimicrobial agents in FRI offers the prospect of improved therapeutic efficacy over that achievable by systemic delivery alone.^{3–7} This is expected because the antimicrobial agent is placed directly within the surgical field and any vascular compromise at the fracture site or surrounding soft tissues does not limit local concentrations as it may do for systemically administered antimicrobials. In addition, with local delivery, the total drug amount may be reduced, yet the local concentrations exceed systemic administration. This improves the impact of antimicrobial agents, while reducing the risk of systemic toxicity.

Many related studies primarily focused on periprosthetic joint infection (PJI), and few investigations have addressed the specific problem of FRI with different opinions and practices on the use of local antimicrobials. Indications, application techniques, dosages, types of antibiotics, elution properties, and pharmacokinetics are poorly defined in the clinical setting, leading to a variation in clinical practice.⁸

Accepted for publication August 9, 2019.

From the *Department of Trauma Surgery, University Hospitals Leuven, Leuven, Belgium; †Hospital for Special Surgery, Limb Lengthening & Complex Reconstruction Service, New York, NY; ‡AO Research Institute Davos, Davos, Switzerland; §Department of Orthopaedic and Trauma Surgery, University Hospital Basel, Basel, Switzerland; ||Department of Orthopedic Surgery, NYU Langone Orthopedic Hospital, New York, NY; ¶Department of Orthopaedic Surgery, Keck School of Medicine, University of Southern California, Los Angeles, CA; **Department of Orthopaedic Surgery and Rehabilitation, Vanderbilt University Medical Center, Nashville, TN; ††Department of Trauma Surgery, University Hospital of Münster, Münster, Germany; and ‡‡The Bone Infection Unit, Nuffield Orthopaedic Centre, Oxford University Hospitals, Oxford, United Kingdom.

The source of funding with respect to hosting the consensus meeting was the AO Foundation (AOTK system and AOTrauma). Open access publication was funded by the AO Foundation and the Orthopaedic Trauma Association.

The authors report no conflict of interest.

W.-J. Metsemakers first authorship and M. A. McNally last (senior) authorship. Members of the FRI consensus group are listed in Acknowledgments section. Reprints: Willem-Jan Metsemakers, MD, PhD, Department of Trauma Surgery, University Hospitals Leuven, Herestraat 49, 3000 Leuven, Belgium (e-mail: willem-jan.metsemakers@uzleuven.be).

Copyright © 2019 The Author(s). Published by Wolters Kluwer Health, Inc. This is an open-access article distributed under the terms of the Creative Commons Attribution-Non Commercial-No Derivatives License 4.0 (CCBY-NC-ND), where it is permissible to download and share the work provided it is properly cited. The work cannot be changed in any way or used commercially without permission from the journal.

DOI: 10.1097/BOT.0000000000001615

Inappropriate and overuse of antibiotics is becoming an important issue in orthopaedic trauma surgery.^{8,9}

This review describes the scientific evidence for currently available local antimicrobial strategies in the management of FRI.

DEBRIDEMENT, IRRIGATION, AND DEAD SPACE MANAGEMENT

Debridement remains critical in the treatment of FRI, and it should include the excision of necrotic and poorly vascularized (ie, nonbleeding) bone/soft tissue and removal of loose implants or foreign bodies. Furthermore, multiple tissue samples should be taken for diagnostic purposes.^{1,2,10}

Debridement is followed by irrigation to further decrease the bacterial load. Open fracture studies showed that irrigation should be performed using normal saline at low pressure to avoid bacterial seeding.^{11–13} Antimicrobial additives are not advised.^{14,15} The optimal amount of irrigation fluid is unknown, and irrigation should be continued until the wound is macroscopically clean.

Debridement in FRI often creates a dead space, which is a poorly perfused defect allowing bacterial proliferation. Furthermore, this environment of low oxygen and pH is ideal for the development of biofilm and bacterial persistence. Therefore, local antimicrobial delivery systems are often used as temporary or definitive strategies for dead space management.¹⁶

LOCAL ANTIMICROBIAL STRATEGIES BASED ON ANTIBIOTICS

Antibiotics Available for Local Use

The chosen antibiotic must provide coverage against a wide range of pathogens (ie, broad-spectrum antibiotic) or against a specific pathogen identified by culture^{17,18}; it must be compatible with and achieve an adequate release from the chosen carrier, and it must have a good toxicity and hypersensitivity profile, and a low rate of resistance.¹⁹ In clinical orthopaedic practice, gentamicin, tobramycin, vancomycin, and clindamycin are the most common commercially available formulations for local antibiotic delivery. They are industrially incorporated into bone cement, collagen, and other bone void fillers that are available for clinical use.⁸ Aside from commercially available preparations, the off-label addition of antibiotics to polymethyl methacrylate (PMMA) is an option. The mechanical needs of the construct may have to be considered because an antibiotic can compromise the strength and setting characteristics of PMMA. In most FRI cases, antibiotic-impregnated PMMA beads and spacers are used for dead space management, and any deterioration of their mechanical properties is not an issue. However, in large segmental defects of the lower extremity, the structural integrity of the spacer (in combination with the osteosynthesis/external fixator) may facilitate weight bearing.

Although local administration of antibiotics is generally considered safe,²⁰ the potential for systemic toxicity should not be neglected.²¹ Also, due consideration should be given to the effect that antibiotics have on cell viability and osteogenic activity in the immediate vicinity of the applied material.^{22,23}

Local antibiotics in very high concentrations produce cellular toxicity and may lead to attenuated fracture healing. This is a concern given that most local delivery systems release a very high dose of antibiotics, in some cases, more than 1000 times the minimal inhibitory concentration (MIC).^{23,24} However, no specific cutoff values for local skeletal toxicity exist. Data from *in vitro* studies indicate increased toxicity—decreased proliferative capacity of osteoblasts and chondrocytes²³—with increased antibiotic concentration and exposure time, which suggests that although higher doses of antibiotic may be better at controlling infection, they are not benign.

Rathbone et al²² showed *in vitro* that the antibiotics that caused the greatest destruction of cell viability and suppression of osteoblast activity included rifampin, minocycline, doxycycline, nafcillin, penicillin, ciprofloxacin, colistin methanesulfonate, and gentamicin. More recent, *in vivo* studies have demonstrated that the local application of gentamicin, in standard available doses, does not interfere with fracture/bone healing.^{25,26} Amikacin, tobramycin, and vancomycin were the least cytotoxic until very high concentrations were used.²² Chu et al²⁷ evaluated the effect of topical vancomycin on mesenchymal stem cells *in vitro*. The authors concluded that there was a dose-dependent cell death with vancomycin use. These data suggested that more vancomycin is harmful *in vitro*, and surgeons should restrict local vancomycin use to the doses currently reported in the available published studies (ie, 1–2 g). Also, Naal et al²⁸ demonstrated that clindamycin levels higher than 500 mg/mL had cytotoxic effects on osteoblasts. The authors suggested that the observed effects could lead to a potential alteration of bone metabolism *in vivo*. Fluoroquinolones have been shown to inhibit growth and extracellular matrix mineralization in osteoblastic cell culture²⁹ and found to inhibit bone growth in an experimental fracture model.³⁰ Fluoroquinolones may therefore compromise the clinical course of fracture healing. A review by Kallala et al³¹ confirmed the negative *in vitro* and *in vivo* effects of high doses of local antibiotics on bone cell metabolism and fracture healing. With this in mind, treating physicians should be careful not to induce local and/or systemic toxicity. Table 1 gives an overview of local antimicrobials and the doses that have been reported in the literature.

Discrepancy exists between *in vitro* and *in vivo* antibiotic release, and these data are not interchangeable. A typical *in vitro* experiment will allow antibiotics to diffuse into a large volume of a solution that may be regularly refreshed. In contrast, *in vivo* antibiotic release may differ because the properties of the fluid medium (amount of fluid, exchange rate) in the vicinity of the material may vary from the *in vitro* situation. *In vitro* data should be considered an indicator of potential antibiotic release rather than a real measure of *in vivo* release.

For PMMA, where the exothermic polymerization process can result in temperatures exceeding 100°C, thermal stability is a key factor in determining the suitability of an antibiotic for incorporation.¹⁹ Moreover, any antimicrobial or carrier should be thermally stable at body temperature for the duration of release.¹⁹ A recent study found that beta-lactam antibiotics degrade quite rapidly at 37°C, whereas excellent

TABLE 1. Overview of Local Antimicrobials and Recommended Local Dosages

Local Antimicrobial	Minimum (Reported) Dose	Maximum (Reported) Dose	Ref.	Examples of Commercially Available Brands	Toxicity*
PMMA (40 g)					Vancomycin:
Commercially available					Allergic reactions
Gentamicin	0.5 g	1 g		Palacos R + G	Nephrotoxicity
Gentamicin + vancomycin	0.5 g + 2 g			Copal G + V	Ototoxicity
Gentamicin + clindamycin	1 g + 1 g			Copal G + C	Neutropenia
Tobramycin	1 g			Simplex P	Gentamicin:
Erythromycin + colistin	0.73 g + 0.24 g			Simplex	Nephrotoxicity
Customized†‡					Ototoxicity
Gentamicin	0.4 g	4.8 g	32		Tobramycin:
Vancomycin	2 g	6 g	32–36		Neurotoxicity
Tobramycin	1.2 g	4.8 g	32,33,37		Nephrotoxicity
Gentamicin + vancomycin	0.5 g + 2 g	4.8 g + 4 g‡	20,38,39		Erythromycin:
Tobramycin + vancomycin	1.2 g + 1 g	3.6 g + 4 g	40,41		Allergic reactions
Gentamicin + tobramycin + vancomycin	0.5 g + 2.4 g + 2 g		42		Ototoxicity
Gentamicin + clindamycin	0.5–1g + 1g		43		QT-interval elongation
Gentamicin + linezolid	0.5 g + 1 g				Reversible disturbance of liver function tests
Gentamicin + daptomycin	0.5 g + 2 g				Colistin:
Gentamicin + fosfomicin	0.5 g + 1–2 g				Allergic reactions
Gentamicin + amphotericin B (liposomal)	0.5 g + 0.2–0.3 g				Neurotoxicity
Gentamicin + amphotericin B (not liposomal)	0.5 g + 0.2 g–0.8 g				Nephrotoxicity
Gentamicin + voriconazol	0.5 g + 0.3–0.6 g				Clindamycin:
Ceramics					Gastrointestinal side effects
Commercially available					Ampicillin:
Tobramycin	262 mg	4 pellets/kg§		Osteoset T (calcium sulfate)	Not to be used in patients with penicillin allergy
Vancomycin + gentamicin	1 g + 240 mg			Stimulan 10cc (calcium sulfate)	Rash
Vancomycin + tobramycin	1 g + 240 mg				
Vancomycin	1 g				
Tobramycin	1.2 g				
Gentamicin	240 mg				
Tobramycin	240 mg				
Gentamicin	175 mg	350 mg		Cerament 10 mL (calcium sulfate/hydroxyapatite)	
Vancomycin	660 mg	1.32 g			
Customized‡					
Vancomycin	250 mg	6 g	44	Osteoset (calcium sulfate) (variable number of batches (25 g) was used)	
Vancomycin	1 g		45	Allomatrix 10 cc (demineralized bone matrix and calcium sulfate)	
Vancomycin + gentamicin	2 g + 240 mg		46	Stimulan 10 cc (calcium sulfate)	
Vancomycin + tobramycin + cefazolin	1 g + 1.2 g + 1 g		47	Stimulan (calcium sulfate)	
Naked antibiotics					
Vancomycin (powder)	0.5 g	6 g¶	48–50		
Tobramycin (liquid)	80 mg/40 mL saline		51,52		
Vancomycin + tobramycin (powder)	1 g + 1.2 g		53		
Ampicillin (powder)	1 g		54		

*General toxicities associated with the use of these antibiotics are reported because reports on side effects of local antibiotic therapy are scarce. All customized dosages reported in this table could not be associated with systemic toxicity. However, studies on the local management of PJI have reported cases of acute renal failure secondary to the use of antibiotic impregnated cement spacers.^{21,55–57} Furthermore, the effect of the antibiotic's concentration on cell viability and osteogenic activity should be considered.²²

†The American Academy of Orthopaedic Surgeons (AAOS) published guidelines for the treatment of PJI using antibiotic-loaded cement spacers. They recommend dosages between 3 and 8 g of antibiotic per batch of cement. Vacuum mixing is contraindicated because it reduces the elution of the antibiotic.⁵⁸ However, for the cement to remain stable and to keep its structural integrity, we recommend to add up to 10% of its weight to the cement batch. Therefore, we would recommend a maximum dose of 4 g per batch (40 g) of PMMA. The integration of β-lactam antibiotics and carbapenems (ie, meropenem) in PMMA was excluded from this table because these antibiotics show poor thermal stability and degrade rapidly at a physiologic temperature of 37°C.¹⁹ Also, fluoroquinolones (ie, ciprofloxacin, levofloxacin), rifampin, tetracyclines (ie, doxycycline, minocycline, tigecycline), and macrolides (ie, azithromycin) were excluded due to their potential local detrimental effects on cell viability and osteogenic activity, as described in vitro.^{19,22,29}

‡The use of more than 1 batch of local antibiotic carrier has been reported, resulting in a higher local dose, without side effects.^{20,59}

§The package insert of Osteoset T calcium sulfate pellets with tobramycin recommends not to exceed the maximum dosage of 4 pellets/kg for adults with normal renal function. An excess usage may cause serum levels of tobramycin to be elevated above the recommended maximum. In these cases, neurotoxicity and nephrotoxicity may manifest. If the bone defect size requires a higher number of pellets to be administered, it is recommended to mix the antibiotic-loaded pellets with standard Osteoset bone graft pellets.

¶Caution should be taken when applying such high doses of vancomycin because clinical evidence on safety is scarce. Only one retrospective study of 981 patients who received topical vancomycin during spinal surgery reported the use of 6 g vancomycin in rare cases. The average dose of vancomycin was 1.16 g in this study.⁴⁹ In general, most reported vancomycin dosages range between 0.5 g and 2 g.^{48,50,60} Depending on the extent of the surgical site that is to be covered, we would recommend to adhere to the upper limit of 2 g.

||Maximum and minimum doses were not always mentioned in the literature.

long-term stability was observed for aminoglycosides, glycopeptides, tetracyclines, and quinolones.¹⁹

Delivery of Antibiotics Without Carrier

In daily clinical practice, this is represented by antibiotics in aqueous solution or powder form. A systematic review demonstrated that local administration of antibiotic (ie, vancomycin) powder significantly decreased infection rates in spine surgery.⁴⁸ However, the only randomized controlled trial (RCT) on this topic found no difference in infection rate when vancomycin powder was used in addition to systemic prophylaxis compared with systemic prophylaxis alone.⁶¹ Other studies reported an increased rate of Gram-negative infections following the introduction of vancomycin powder in the operative bed in spine surgery.^{49,62} The use of intrawound antibiotic powder has not been studied extensively in orthopaedic trauma. Few preclinical and clinical studies report the technique and even a positive outcome, but comparative studies are lacking.^{53,63–66} An ongoing multicenter prospective RCT run by the Major Extremity Trauma Research Consortium is assessing whether local vancomycin therapy can reduce infection rates after operative treatment of fractures at high risk of infection.⁶⁷

Antibiotics can also be administered in aqueous solution (eg, tobramycin). These antibiotic solutions have already been used for many years, and experimental and clinical data suggest that this method of delivery is effective.^{51,68} In a case series, the local injection of aminoglycosides was found to reduce the infection rate in open fractures.⁵²

Delivering “naked” antibiotics does not require a specialized carrier, and therefore, the cost is lower. However, an important drawback to this method is the fact that high local antibiotic levels cannot be sustained.

To date, the application of antibiotics without any carrier has not been documented in human clinical trials focused on the treatment of FRI, and further research is required to make recommendations.

Delivery of Antibiotics by Carrier

Autograft

Autograft provides a combination of scaffolding and biologically active cells to enhance healing at fracture nonunion sites. Methods for obtaining autograft and potential sites for harvest are numerous.^{69,70} Autograft has been well studied in its natural state,⁷¹ complimenting an induced membrane approach,^{72–76} or combined with antibiotics.^{77,78} Autograft exhibits some natural resistance to infection, as evidenced by the Papineau technique,^{79,80} where the graft is applied into open wounds that are left to heal for months through neopithelialization. However, an experimental study revealed that when bone marrow aspirate was injected into active sites of osteomyelitis, the resulting inflammation created significantly more bony destruction.⁸¹ This supports the importance of debridement of all infected, poorly vascularized tissue before grafting.⁸²

Autograft can also be used as a carrier for local antibiotics. In theory, mixing antimicrobials with autograft

provides the optimal solution of dead space management, enhanced biology, and infection control and has been used successfully for second-stage grafting of bone defects.⁷³ As mentioned earlier, part of the resistance to using antibiotics with fresh autograft is concern regarding cytotoxic effects on osteocytes/osteoblasts.

A number of clinical studies have been performed on antibiotic-loaded autograft. Lindsey et al⁸³ showed that tobramycin could be mixed with autograft without negative effects on healing. A study by Chan et al⁸⁴ reported the effects of antibiotic-impregnated cancellous bone grafting on infection elimination and bone incorporation in patients with infected tibial nonunions. The authors used different antibiotics targeted to the infecting organisms that were found during the initial debridement (ie, first stage). The results suggested that impregnated antibiotics have no adverse effects on autogenic cancellous bone graft incorporation. Furthermore, recurrence rates were lower in the group that received local antibiotics. In a study on infected tibial nonunions, vancomycin-impregnated cancellous bone graft was a safe method, with no recurrence of infection.⁸⁵ However, the study had a reoperation rate of 28% for “healing disturbances.”

Because scientific evidence from large clinical series is lacking and optimal antibiotic doses are currently not available, the routine combination of local antimicrobials with autogenic cancellous bone graft is not recommended as the standard of care.

Allograft

The use of human allograft bone avoids the morbidity of harvesting autologous bone graft but poses a potential risk for infection when used in a contaminated site both by introducing bacteria⁸⁶ and by serving as a sequestrum for bacteria in the previously infected site.⁸⁷ Also, allograft bone lacks the osteoinductive properties of autograft. For these reasons, allograft has not found wide application in FRIs associated with bone defects.

Modification of allograft tissue has allowed it to become a carrier for antibiotics.⁸⁸ These modifications include porphyrin adsorption,⁸⁹ antibiotic impregnation,^{90–92} antibiotic tethering,⁹³ and chitosan–heparin coating.⁹⁴ Studies show that when mixing bone allografts with antibiotics, their storage capacity and release profile vastly exceeds that of PMMA.⁸⁸

In a series of 45 patients undergoing revision of infected hip and knee prosthetic replacement with impaction grafting, femoral head allografts were soaked in an antibiotic solution and revision surgery was done in one stage, eradicating infection in 96% of the patients.⁹⁵ Although positive results have been published, surgeons should be aware that after release of the antimicrobial substance, allograft still functions as a foreign body.

Although the incorporation of antimicrobials in bone graft (ie, autograft and allograft) has been studied for decades with promising results, there is currently insufficient information available with respect to the optimal carrier (ie, allograft or autograft), optimal antibiotic, and preferred doses (ie, local and systemic toxicity profiles).

Polymethyl Methacrylate

PMMA is a commonly used delivery vehicle for antibiotic therapy. The most popular drugs used are aminoglycosides (ie, gentamicin—tobramycin) and vancomycin.^{96,97} These antibiotics exert a synergistic effect with superior elution properties when used together.⁹⁸ Other antimicrobials can also be used, including daptomycin,⁹⁹ amikacin,¹⁰⁰ and voriconazole.¹⁰¹ The amount of antimicrobials mixed into PMMA significantly varies between studies, specifically with respect to off-label mixing procedures, yet it is unclear if the success rate depends on the quantity of drug used. Table 1 gives an overview of standard available and recommended doses of antimicrobials mixed with PMMA.

PMMA has been used as an antibiotic carrier for decades.¹⁰² It delivers a high dose of antibiotic and may be used in spacer or bead form for both prevention and treatment of FRI.¹⁰³ PMMA can be used as a spacer (eg, Masquelet technique), or it can be applied in the shape of beads at the site of infection.¹⁰⁴ The local application of antibiotics to the intramedullary (IM) canal can be achieved by coating ball-tipped guide wires or flexible rods with antibiotic cement. Such coating can be achieved by pumping PMMA into a large chest tube or using a “hand rolling technique” (Fig. 1). This IM spacer technique is often used for the 2-stage treatment of infected long bone nonunions and has shown good results.^{105,106}

The off-label coating of definitive internal implants, including plates¹⁰⁷ and locked IM nails,^{96,97,108–110} with PMMA has also been a treatment option for FRI. These self-made coated implants can provide an alternative to staged treatment with external fixation followed by definitive internal fixation.¹¹¹ Antibiotic-coated implants must often be custom molded (handmade) in the operating room using PMMA and a combination of antibiotics (Fig. 1). The antibiotic-coated locked IM nail has been used with increasing frequency for internal fixation of long bone fractures⁴⁰ and in complex knee and ankle fusion cases.¹¹² Disadvantages to the use of these implants include controlling the heterogeneity of the antibiotic distribution in the cement, undulations in the diameter of the nail coating, and the release profile of the antibiotics from the PMMA.

The type of PMMA used will also affect the elution characteristics. When PMMA is more porous, it allows antibiotics to escape from the cement matrix, more readily improving antibiotic concentrations.¹¹³ Furthermore, the addition of vancomycin or amphotericin B antibiotic powder in distilled water before mixing with bone cement improves antibiotic release.¹¹⁴ Porosity will improve the elution for bone void PMMA spacers and beads but is not ideal for coating implants or cement rods where fragmentation complicates cement removal.

The variable antibiotic elution rates of PMMA and the requirement for removal has led to the investigation of alternative carriers. A systematic review showed that, despite the long experience with its use and the theoretical advantages, there are no well-executed, prospective studies investigating the efficacy of antibiotic-loaded PMMA beads in treating orthopaedic infections.¹¹⁵ However, studies with

respect to the prevention of FRI describe an improved clinical outcome when using PMMA beads, especially in open fractures.¹⁰³

In addition, van de Belt et al¹¹⁶ evaluated the release profiles of 6 types of bone cements in vitro and found that the released antibiotic fell below the detection limit after 1 week and only 4%–17% of the incorporated antibiotic was released. In a clinical study by Neut et al,¹¹⁷ the authors retrieved gentamicin-loaded PMMA beads after revision surgery for PJIs. Cultures were positive for bacteria on gentamicin-loaded beads in 90% of the patients. A significant amount of these strains proved to be gentamicin resistant, which raises concerns over the development of antibiotic resistance due to prolonged release at subtherapeutic levels.

Local delivery of antibiotics is not a substitute for thorough debridement. In the presence of remaining avascular tissue and foreign bodies, bacteria may remain viable despite initial high doses of antibiotics. Also, PMMA spacers/beads are not intended for permanent implantation but are temporarily used for dead space management and local antibiotic delivery. During the second-stage procedure, they are removed, and the dead space is addressed with a reconstructive procedure (eg, bone grafting).

Ceramics

This review describes 2 types of ceramics that are used in FRI patients: biodegradable ceramics and bioactive glasses. Both are biodegradable substances, which raise the possibility of single-stage surgery with definitive soft tissue closure, avoiding the need for subsequent surgery for spacer (eg, PMMA) removal.¹⁶

Biodegradable Ceramics

The principle types of biodegradable ceramics available for antibiotic delivery are based on either calcium sulfate or calcium phosphate.¹⁶ The reported antibiotic elution profiles of both remain fairly similar, with the delivery of antibiotics above the MIC for between 3 and 4 weeks.^{16,118} This elution profile is superior to that of PMMA. For example, Howlin et al¹¹⁹ showed that calcium sulfate beads maintained antibiotic concentrations above MIC for 39 days compared with PMMA, which was only effective for 12 days.

The most extensively investigated biodegradable ceramic in the surgical management of FRI and chronic osteomyelitis is Osteoset T [Wright Medical, Memphis, TN; Food and Drug Administration (FDA) approved].^{120–123} In an RCT, 30 patients with infected long bones received either Osteoset T or antibiotic-loaded PMMA beads with no difference in infection eradication or union.¹²⁰ However, significantly more surgical procedures were needed in the cement group (15 vs. 7; $P = 0.04$). In a randomized trial, debridement alone was statistically less effective than debridement with implanted calcium sulfate with tobramycin (60% vs. 80%) in medullary infections.¹²² In a series of 195 cases of long-bone infection, including 110 infected fractures, Osteoset T was an effective antibiotic carrier, with 91% infection eradication in single-stage surgery.¹²⁴ However, bone formation was poor, and posttreatment fractures occurred through the defect in 4.6% of cases.

In an attempt to improve the performance of inorganic ceramics, Cerament (Bonesupport, Lund, Sweden; FDA approval for an investigational device exemption study) with gentamicin or vancomycin has been developed. It is a flowable, cold curing, biphasic composite containing 60% calcium sulfate and 40% hydroxyapatite. It forms a paste that can be injected into bone defects.⁵⁹ In a series of 100 cases, including 71 FRIs, Cerament G eradicated infection in 96%.⁵⁹ A comparison of the outcomes for Osteoset T and Cerament G in the surgical treatment of chronic osteomyelitis showed fewer wound healing problems in the Cerament G group, with infection recurrence and refractures being 2 times less likely compared with those in the Osteoset T group.¹²⁵

Cerament G can be injected into the IM canal in a fluid state before nail insertion. The carrier coats the surface of the nail, potentially protecting it from colonization and delivering a high local dose of antibiotic. Cerament G has been evaluated in a series of 12 infected nonunions with single-stage revision fixation. All 12 were infection free at a minimum of 1 year, and 11 healed with single-stage surgery.¹²⁶

Bioactive Glass

Bioactive glass, a synthetic silicate material, has been shown to have antibacterial properties that can allow osteoconduction and possibly osteostimulation.¹²⁷ Most data in FRI is available for the bioactive glass S53P4 (Bioglass; BonAlive Biomaterials Ltd, Turku, Finland; not FDA approved). Upon implantation, bioactive glass S53P4 undergoes chemical degradation, thereby releasing sodium and calcium ions. Eventually, together with an increase in pH, this leads to the conversion of the glass into a carbonate-substituted hydroxyapatite-like layer similar to bone.^{127,128} The intrinsic antibacterial property of bioactive glass S53P4 is due to the ion dissolution process that starts immediately after the bone substitute has been implanted into the body.¹²⁹ The ion release at the bioactive glass surface induces an increase in pH and also an osmotic pressure around the bioactive glass. These phenomena have shown to kill both planktonic bacteria and bacteria in biofilm *in vitro*.¹³⁰ In an *in vitro* study, bioactive glass S53P4 was compared to antibiotic-loaded PMMA, with both showing comparable antibacterial properties against multidrug-resistant bacteria.¹³¹

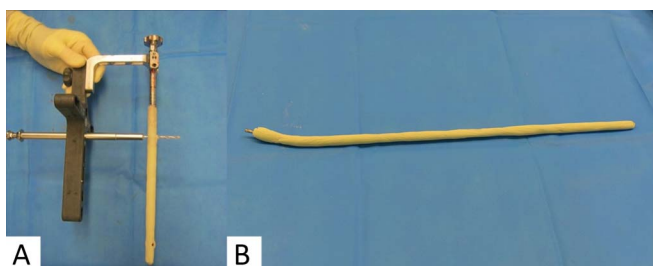


FIGURE 1. A, Polymethyl methacrylate (PMMA)-coated humeral nail. The nail was custom molded (handmade) in the operating room using PMMA and a combination of antibiotics. B, PMMA spacer for application in the IM canal of the tibia. The application of PMMA on a rod was achieved using a hand rolling technique.

Clinical studies showed a success rate of approximately 90% in the treatment of chronic osteomyelitis, using bioactive glass S53P4.^{129,132} However, Geurts et al¹³³ treated 18 patients in a low-income country with a success rate of only 38%.

Poly(D,L-Lactide) (PDLLA)

The clinical application of antibiotics through a bio-degradable implant [Poly(D,L-Lactide) (PDLLA)] coating is a relatively new development.¹³⁴ Antibiotic-coated implants do not necessitate additional removal surgeries or delay wound closure. The only PDLLA-coated fracture-related implant that is currently commercially available is the PRO-ject tibia nail (DepuySynthes; Johnson/Johnson Company, Inc, New Brunswick, NJ; not FDA approved). It is coated with a layer of PDLLA impregnated with gentamicin. The coating releases gentamicin over a period of 2 weeks, with a burst release in the first days.

Two clinical studies evaluated these gentamicin-coated tibia nails in acute complex fractures and revision cases. In both studies, no postoperative infectious complications were documented.^{135,136} Antibiotic-PDLLA-coated implants may be a promising option for the prevention of FRI in open fracture or revision cases.

Collagen Sponges

Collagen is a natural polymer that can be used for drug delivery.¹³⁷ Antibiotic impregnated collagen sponges are not a new development,¹³⁸ but clinical studies in the field of FRI are scarce.¹³⁹ Initially, these sponges were developed to prevent infections by providing high local gentamicin concentrations, but more recently, authors also suggested their use in the treatment of infection.¹⁴⁰ Although previous studies suggested promising results with respect to infection prevention in open fractures,¹³⁹ a recent RCT showed that the use of 2 gentamicin-collagen sponges compared with no intervention did not reduce the 90-day sternal wound infection rate.¹⁴¹ Treatment-related studies are all retrospective and published at least 2 decades ago, with variable results.^{138,142,143}

Hydrogels

Hydrogels are a newer option for the local delivery of antibiotic agents. Hydrogels in general consist of a polymerized macromolecule that is hydrated with water (and antibiotics) to form easily manageable materials with gel-like properties. Hydrogels can be injectable, allow for minimally invasive application, can sustain antibiotic release,¹⁴⁴ are bio-degradable, and thus do not require removal surgery. Hydrogels have been studied in more detail in preclinical studies, showing prophylactic efficacy in rabbit FRI and PJI models.^{25,145} Furthermore, these gels have shown to allow normal bone apposition and fracture healing.^{25,146}

Clinical studies focusing on FRI are scarce. In a recent RCT, 256 patients who were scheduled to receive osteosynthesis for a closed fracture were randomly assigned to an antibiotic-loaded hydrogel or a control group.¹⁴⁷ The authors concluded that there was a reduced infection rate in the hydrogel group, without any detectable adverse events or side effects.

TABLE 2. Key Recommendations

The critical element for success is the removal of all dead or poorly vascularized tissue before the use of any type of local antimicrobial strategy. Irrigation should be performed using normal saline at low pressure to avoid bacterial seeding deeper into soft tissue and bone. The use of antimicrobial additives is currently not advised because they may add toxicity, although clinical data within this field are scarce.

The use of naked antibiotics (eg, vancomycin powder) has not been well documented in treatment of FRI and further research is required.

Although the incorporation of antimicrobials in bone graft (ie, autograft and allograft) has been studied for decades with promising results, information with respect to the optimal carrier (ie, allograft or autograft), optimal antibiotic, and preferred doses (ie, local and systemic toxicity profiles) are currently not well defined.

PMMA remains the best understood carrier for antibiotics. The surgeon must select the correct antimicrobial(s), the state (ie, liquid or powder), and dosage; the cement type, the use of a porogen, and the mixing method, in combination with the final form and function of the PMMA (spacer, bead, or coating).

The off-label use of IM PMMA-coated rods or nails, loaded with antibiotics, currently remains a good treatment option in cases of FRI in long bones.

Biodegradable ceramics offer advantages over PMMA, including no need for additional removal surgery and an improved release profile (when carrying antimicrobials).

Although higher doses of antimicrobials may be better for infection control, they may not be benign.

Although local antimicrobials are mostly safe, certain patients are at risk of local and systemic toxicity (eg, nephrotoxicity). The total dose of antibiotic used and anticipated local concentration should be considered and preoperative patient comorbidities.

Multicenter prospective studies comparing the best current practices with a uniform product and standard antibiotic concentrations would provide better data for informed surgical planning.

FRI, fracture-related infection; PMMA, polymethyl methacrylate; IM, intramedullary.

Overall, although hydrogels have the disadvantage of lacking structural strength and release antimicrobials for a shorter period compared with biodegradable ceramics, the advantage is a rapid resorption, thereby leaving no foreign body for biofilm formation.

NONANTIBIOTIC ANTIMICROBIAL STRATEGIES

Silver

Silver has been used as a disinfectant for many centuries.^{148,149} Silver is used in its metallic form as a nanoparticle or in silver-containing polymers and composites.¹⁵⁰ For orthopaedic applications, silver has been introduced into hydroxyapatite and bone cement and as a coating for trauma devices.¹⁵¹

The toxicity of silver to eukaryotic cells has been one of the major concerns with respect to its use as an implant coating or as antimicrobial in a bone void filler.^{149,152} Despite this, there are numerous silver-functionalized implants and wound dressings available clinically,^{153–156} with few reports of induced toxicity.¹⁵⁷ The development and spread of silver resistance in FRI pathogens is another concern that could limit silver-based interventions. In general, resistance to silver is rare, and to date, there are no reports in Gram-positive species, which account for a majority of FRI pathogens.

Overall clinical studies demonstrate a trend in reducing infection with silver-coated central venous catheters, urinary catheters, and ventilator endotracheal tubes.^{154–156} Similar positive results were achieved with a silver-coated megaprosthesis, which has been used in revision arthroplasty due to infection or in tumor resection.¹⁵⁸ Silver-coated external fixation pins have also been tested in patients, although a lack of efficacy and elevated serum silver levels have limited the use of these pins.¹⁵⁹

Bacteriophages

Bacteriophages (phages) are viruses that selectively infect, multiply within, and subsequently lyse bacteria. The

use of phages for the treatment of bacterial infections is not a novel concept, but it has been applied since the start of the 20th century. With the advent of antibiotics, however, phage therapy lost ground. Although phages have been applied for almost a century in eastern Europe, clinical studies are limited.^{160–162} Currently, with the increase in multidrug-resistant strains, phage therapy is regaining interest.¹⁶³ Clinical and experimental studies on orthopaedic implant-related infections have shown promising results.^{164,165} Future research on this topic, with well-conducted clinical trials, is important.^{166,167}

CONCLUSIONS

In addition to bony stability and soft tissue cover, the treatment pathway for FRI is founded on successful debridement and irrigation of bone and soft tissue, in combination with systemic and local antibiotic administration. This review described the scientific evidence for dead space management with a focus on currently available local antimicrobial strategies in the management of FRI. Key recommendations are summarized in Table 2.

ACKNOWLEDGMENTS

This manuscript was developed by the FRI consensus group [supported by the AO Foundation, Orthopaedic Trauma Association (OTA), Pro-Implant Foundation and the European Bone and Joint Infection Society (EBJIS)].

The authors specifically would like to thank the Anti-Infection Task Force (AOTK System; Claas Albers) and the Clinical Priority Program Bone Infection (AO Trauma; Philipp Buescher) for their support of the consensus meetings that were convened in 2016 (Davos, Switzerland) and 2018 (Zürich, Switzerland). Furthermore, The authors would like to thank Jolien Onsea (department of Trauma Surgery, University Hospitals Leuven) and Lois Wallach (AOTK System)

for their assistance in preparing and proofreading this manuscript.

Members of the FRI Consensus Group: W-J. Metsemakers: Department of Trauma Surgery, University Hospitals Leuven, Leuven, Belgium (chair); W. T. Obremskey: Department of Orthopaedic Surgery and Rehabilitation, Vanderbilt University Medical Center, Nashville, TN (chair); M. A. McNally: The Bone Infection Unit, Nuffield Orthopaedic Centre, Oxford University Hospitals, Oxford, United Kingdom (chair); Nick Athanasou: The Bone Infection Unit, Nuffield Orthopaedic Centre, Oxford University Hospitals, Oxford, United Kingdom; Bridget L. Atkins: The Bone Infection Unit, Nuffield Orthopaedic Centre, Oxford University Hospitals, Oxford, United Kingdom; Olivier Borens: Orthopedic Department of Septic Surgery, Orthopaedic-Trauma Unit, Department for the Musculoskeletal System, CHUV, Lausanne, Switzerland; Melissa Depypere: Department of Laboratory Medicine, University Hospitals Leuven, Leuven, Belgium; Henrik Eckardt: Department of Orthopaedic and Trauma Surgery, University Hospital Basel, Basel, Switzerland; K. A. Egol: Department of Orthopedic Surgery, NYU Langone Orthopedic Hospital, New York, NY; William Foster: Department of Orthopaedic Surgery, Virginia Commonwealth University, Richmond, VA; A. T. Fragomen: Hospital for Special Surgery, Limb Lengthening & Complex Reconstruction Service, New York, NY; Geertje A.M. Goovaert: Department of Trauma Surgery, University of Utrecht, University Medical Center Utrecht, Utrecht, the Netherlands; Sven Hungerer: Department of Joint Surgery and Arthroplasty, Trauma Center Murnau, Murnau, Germany and Paracelsus Medical University (PMU) Salzburg, Salzburg, Austria; Stephen L. Kates: Department of Orthopaedic Surgery, Virginia Commonwealth University, Richmond, VA; Richard Kuehl: Department of Infectious Diseases and Hospital Epidemiology, University Hospital of Basel, Basel, Switzerland; Leonard Marais: Department of Orthopaedics, School of Clinical Medicine, University of KwaZulu-Natal, Durban, South Africa; Ian McFadyen: Department of Orthopaedic Surgery, University Hospitals of North Midlands, Stoke-on-Trent, United Kingdom; Mario Morgenstern: Department of Orthopaedic and Trauma Surgery, University Hospital Basel, Basel, Switzerland; T. F. Moriarty: AO Research Institute Davos, Davos, Switzerland; Peter Ochsner: Medical University Basel, Basel, Switzerland; Alex Ramsden: The Bone Infection Unit, Nuffield Orthopaedic Centre, Oxford University Hospitals, Oxford, United Kingdom; M. Raschke: Department of Trauma Surgery, University Hospital of Münster, Münster, Germany; R. Geoff Richards: AO Research Institute Davos, Davos, Switzerland; Carlos Sancineto: Department of Orthopaedics, Hospital Italiano de Buenos Aires, Buenos Aires, Argentina; C. Zalavras: Department of Orthopaedic Surgery, Keck School of Medicine, University of Southern California, Los Angeles, CA; Eric Senneville: Department of Infectious Diseases, Gustave Dron Hospital, University of Lille, Lille, France; Andrej Trampuz: Center for Musculoskeletal Surgery, Charité—Universitätsmedizin Berlin, corporate member of Freie Universität Berlin, Humboldt-Universität zu Berlin, and Berlin Institute of Health, Berlin,

Germany; Michael H. J. Verhofstad: Department of Trauma Surgery, Erasmus University Medical Centre, Rotterdam, the Netherlands; Werner Zimmerli: Interdisciplinary Unit for Orthopedic Infections, Kantonsspital Baselland, Liestal, Switzerland.

REFERENCES

1. Metsemakers WJ, Kuehl R, Moriarty TF, et al. Infection after fracture fixation: current surgical and microbiological concepts. *Injury*. 2018;49:511–522.
2. McNally MA. Infection after fracture. In: Kates S, Borens O, eds. *Principles of Orthopedic Infection*. New York, NY: Thieme Verlag; 2016:139–165.
3. Patzakis MJ, Mazur K, Wilkins J, et al. Septopal beads and autogenous bone grafting for bone defects in patients with chronic osteomyelitis. *Clin Orthop Relat Res*. 1993;295:112–118.
4. Calhoun JH, Henry SL, Anger DM, et al. The treatment of infected nonunions with gentamicin-polymethylmethacrylate antibiotic beads. *Clin Orthop Relat Res*. 1993;295:23–27.
5. Blaha JD, Calhoun JH, Nelson CL, et al. Comparison of the clinical efficacy and tolerance of gentamicin PMMA beads on surgical wire versus combined and systemic therapy for osteomyelitis. *Clin Orthop Relat Res*. 1993;295:8–12.
6. Turner TM, Urban RM, Hall DJ, et al. Local and systemic levels of tobramycin delivered from calcium sulfate bone graft substitute pellets. *Clin Orthop Relat Res*. 2005;437:97–104.
7. Rand BC, Penn-Barwell JG, Wenke JC. Combined local and systemic antibiotic delivery improves eradication of wound contamination: an animal experimental model of contaminated fracture. *Bone Joint J*. 2015;97-B:1423–1427.
8. Hake ME, Young H, Hak DJ, et al. Local antibiotic therapy strategies in orthopaedic trauma: practical tips and tricks and review of the literature. *Injury*. 2015;46:1447–1456.
9. Cooper C, Homer C, Barlow G, et al. A survey of practice and opinions on the use of topical antibiotics to prevent surgical site infection: more confusion than consensus. *J Antimicrob Chemother*. 2018;73:1978–1983.
10. Dudareva M, Barrett L, Figtree M, et al. Sonication versus tissue sampling for diagnosis of prosthetic joint and other orthopedic device-related infections. *J Clin Microbiol*. 2018;56.
11. Bhandari M, Bhandari M, Jeray KJ, et al. A trial of wound irrigation in the initial management of open fracture wounds. *N Engl J Med*. 2015;373:2629–2641.
12. Anglen JO. Wound irrigation in musculoskeletal injury. *J Am Acad Orthop Surg*. 2001;9:219–226.
13. Draeger RW, Dahners LE. Traumatic wound debridement: a comparison of irrigation methods. *J Orthop Trauma*. 2006;20:83–88.
14. Yun HC, Murray CK, Nelson KJ, et al. Infection after orthopaedic trauma: prevention and treatment. *J Orthop Trauma*. 2016;30(suppl 3):S21–S26.
15. Penn-Barwell JG, Murray CK, Wenke JC. Comparison of the antimicrobial effect of chlorhexidine and saline for irrigating a contaminated open fracture model. *J Orthop Trauma*. 2012;26:728–732.
16. Ferguson J, Diefenbeck M, McNally M. Ceramic biocomposites as biodegradable antibiotic carriers in the treatment of bone infections. *J Bone Joint Infect*. 2017;2:38–51.
17. Sheehy SH, Atkins BA, Bejon P, et al. The microbiology of chronic osteomyelitis: prevalence of resistance to common empirical antimicrobial regimens. *J Infect*. 2010;60:338–343.
18. Olesen UK, Juul R, Bonde CT, et al. A review of forty five open tibial fractures covered with free flaps. Analysis of complications, microbiology and prognostic factors. *Int Orthop*. 2015;39:1159–1166.
19. Samara E, Moriarty TF, Decosterd LA, et al. Antibiotic stability over six weeks in aqueous solution at body temperature with and without heat treatment that mimics the curing of bone cement. *Bone Joint Res*. 2017;6:296–306.
20. Springer BD, Lee GC, Osmon D, et al. Systemic safety of high-dose antibiotic-loaded cement spacers after resection of an infected total knee arthroplasty. *Clin Orthop Relat Res*. 2004;427:47–51.

21. van Raaij TM, Visser LE, Vulto AG, et al. Acute renal failure after local gentamicin treatment in an infected total knee arthroplasty. *J Arthroplasty*. 2002;17:948–950.
22. Rathbone CR, Cross JD, Brown KV, et al. Effect of various concentrations of antibiotics on osteogenic cell viability and activity. *J Orthop Res*. 2011;29:1070–1074.
23. Antoci V Jr, Adams CS, Hickok NJ, et al. Antibiotics for local delivery systems cause skeletal cell toxicity in vitro. *Clin Orthop Relat Res*. 2007;462:200–206.
24. McLaren AC. Alternative materials to acrylic bone cement for delivery of depot antibiotics in orthopaedic infections. *Clin Orthop Relat Res*. 2004;427:101–106.
25. Ter Boo GJ, Schmid T, Zderic I, et al. Local application of a gentamicin-loaded thermo-responsive hydrogel allows for fracture healing upon clearance of a high *Staphylococcus aureus* load in a rabbit model. *Eur Cell Mater*. 2018;35:151–164.
26. Fassbender M, Minkwitz S, Kronbach Z, et al. Local gentamicin application does not interfere with bone healing in a rat model. *Bone*. 2013;55:298–304.
27. Chu S, Chen N, Dang ABC, et al. The effects of topical vancomycin on mesenchymal stem cells: more may not be better. *Int J Spine Surg*. 2017;11:12.
28. Naal FD, Salzmann GM, von Knoch F, et al. The effects of clindamycin on human osteoblasts in vitro. *Arch Orthop Trauma Surg*. 2008;128:317–323.
29. Holtom PD, Pavkovic SA, Bravos PD, et al. Inhibitory effects of the quinolone antibiotics trovafloxacin, ciprofloxacin, and levofloxacin on osteoblastic cells in vitro. *J Orthop Res*. 2000;18:721–727.
30. Huddleston PM, Steckelberg JM, Hanssen AD, et al. Ciprofloxacin inhibition of experimental fracture healing. *J Bone Joint Surg Am*. 2000;82:161–173.
31. Kallala R, Graham SM, Nikkiah D, et al. In vitro and in vivo effects of antibiotics on bone cell metabolism and fracture healing. *Expert Opin Drug Saf*. 2012;11:15–32.
32. Jaebon T. Polymethylmethacrylate: properties and contemporary uses in orthopaedics. *J Am Acad Orthop Surg*. 2010;18:297–305.
33. Holtom PD, Patzakis MJ. Newer methods of antimicrobial delivery for bone and joint infections. *Instr Course Lect*. 2003;52:745–749.
34. Morimoto S, Futani H, Ogura H, et al. Successful reimplantation of total femoral prosthesis after deep infection. *J Arthroplasty*. 2003;18:216–220.
35. Qiang Z, Jun PZ, Jie XJ, et al. Use of antibiotic cement rod to treat intramedullary infection after nailing: preliminary study in 19 patients. *Arch Orthop Trauma Surg*. 2007;127:945–951.
36. Sancineto CF, Barla JD. Treatment of long bone osteomyelitis with a mechanically stable intramedullar antibiotic dispenser: nineteen consecutive cases with a minimum of 12 months follow-up. *J Trauma*. 2008;65:1416–1420.
37. Madanagopal SG, Seligson D, Roberts CS. The antibiotic cement nail for infection after tibial nailing. *Orthopedics*. 2004;27:709–712.
38. Jung J, Schmid NV, Kelm J, et al. Complications after spacer implantation in the treatment of hip joint infections. *Int J Med Sci*. 2009;6:265–273.
39. Kanakaris NK, Morell D, Gudipati S, et al. Reaming Irrigator Aspirator system: early experience of its multipurpose use. *Injury*. 2011;42(suppl 4):S28–S34.
40. Bhadra AK, Roberts CS. Indications for antibiotic cement nails. *J Orthop Trauma*. 2009;23:S26–S30.
41. Zalavras CG, Patzakis MJ, Holtom P. Local antibiotic therapy in the treatment of open fractures and osteomyelitis. *Clin Orthop Relat Res*. 2004;427:86–93.
42. Mauffrey C, Chaus GW, Butler N, et al. MR-compatible antibiotic interlocked nail fabrication for the management of long bone infections: first case report of a new technique. *Patient Saf Surg*. 2014;8:14.
43. Kühn KD, Renz N, Trampuz A. Lokale antibiotikatherapie. *Unfallchirurg*. 2017;120:561–572.
44. Wahl P, Guidi M, Benninger E, et al. The levels of vancomycin in the blood and the wound after the local treatment of bone and soft-tissue infection with antibiotic-loaded calcium sulphate as carrier material. *Bone Joint J*. 2017;99-B:1537–1544.
45. Bibbo C, Patel DV. The effect of demineralized bone matrix-calcium sulfate with vancomycin on calcaneal fracture healing and infection rates: a prospective study. *Foot Ankle Int*. 2006;27:487–493.
46. Badie AA, Arafa MS. One-stage surgery for adult chronic osteomyelitis: concomitant use of antibiotic-loaded calcium sulphate and bone marrow aspirate. *Int Orthop*. 2019;43:1061–1070.
47. Lum ZC, Pereira GC. Local bio-absorbable antibiotic delivery in calcium sulfate beads in hip and knee arthroplasty. *J Orthop*. 2018;15:676–678.
48. Bakhsheshian J, Dahdaleh NS, Lam SK, et al. The use of vancomycin powder in modern spine surgery: systematic review and meta-analysis of the clinical evidence. *World Neurosurg*. 2015;83:816–823.
49. Ghobrial GM, Thakkar V, Andrews E, et al. Intraoperative vancomycin use in spinal surgery: single institution experience and microbial trends. *Spine*. 2014;39:550–555.
50. Yao R, Tan T, Tee JW, et al. Prophylaxis of surgical site infection in adult spine surgery: a systematic review. *J Clin Neurosci*. 2018;52:5–25.
51. Cancienne JM, Burrus MT, Weiss DB, et al. Applications of local antibiotics in orthopedic trauma. *Orthop Clin North Am*. 2015;46:495–510.
52. Lawing CR, Lin FC, Dahners LE. Local injection of aminoglycosides for prophylaxis against infection in open fractures. *J Bone Joint Surg Am*. 2015;97:1844–1851.
53. Owen MT, Keener EM, Hyde ZB, et al. Intraoperative topical antibiotics for infection prophylaxis in pelvic and acetabular surgery. *J Orthop Trauma*. 2017;31:589–594.
54. Takeuchi M, Wakao N, Kamiya M, et al. A double-blind randomized controlled trial of the local application of vancomycin versus ampicillin powder into the operative field for thoracic and/or lumbar fusions. *J Neurosurg Spine*. 2018;29:553–559.
55. Curtis JM, Sternhagen V, Batts D. Acute renal failure after placement of tobramycin-impregnated bone cement in an infected total knee arthroplasty. *Pharmacotherapy*. 2005;25:876–880.
56. Dovas S, Liakopoulos V, Papatheodorou L, et al. Acute renal failure after antibiotic-impregnated bone cement treatment of an infected total knee arthroplasty. *Clin Nephrol*. 2008;69:207–212.
57. Patrick BN, Rivey MP, Allington DR. Acute renal failure associated with vancomycin- and tobramycin-laden cement in total hip arthroplasty. *Ann Pharmacother*. 2006;40:2037–2042.
58. Clyburn TA, Cui Q. *Antibiotic Laden Cement: Current State of the Art*. AAOS Now. 2007;1:17–18.
59. McNally MA, Ferguson JY, Lau AC, et al. Single-stage treatment of chronic osteomyelitis with a new absorbable, gentamicin-loaded, calcium sulphate/hydroxyapatite biocomposite: a prospective series of 100 cases. *Bone Joint J*. 2016;98-B:1289–1296.
60. Fleischman AN, Austin MS. Local intra-wound administration of powdered antibiotics in orthopaedic surgery. *J Bone Joint Infect*. 2017;2:23–28.
61. Tubaki VR, Rajasekaran S, Shetty AP. Effects of using intravenous antibiotic only versus local intrawound vancomycin antibiotic powder application in addition to intravenous antibiotics on postoperative infection in spine surgery in 907 patients. *Spine*. 2013;38:2149–2155.
62. Adogwa O, Elsamadicy AA, Sergesketter A, et al. Prophylactic use of intraoperative vancomycin powder and postoperative infection: an analysis of microbiological patterns in 1200 consecutive surgical cases. *J Neurosurg Spine*. 2017;27:328–334.
63. Firoozabadi R, Miranda S, Tornetta P III. Technique for placement of peri-implant antibiotics using antibiotic putty. *J Orthop Trauma*. 2017;31:e442–e445.
64. Shiels SM, Tennent DJ, Wenke JC. Topical Rifampin Powder for Orthopaedic Trauma Part I: rifampin powder reduces recalcitrant infection in a delayed treatment musculoskeletal trauma model. *J Orthop Res*. 2018;36:3136–3141.
65. Tennent DJ, Shiels SM, Sanchez CJ Jr, et al. Time-dependent effectiveness of locally applied vancomycin powder in a contaminated traumatic orthopaedic wound model. *J Orthop Trauma*. 2016;30:531–537.
66. Caroom C, Moore D, Mudaliar N, et al. Intra-wound vancomycin powder reduces bacterial load in contaminated open fracture model. *J Orthop Trauma*. 2018;32:538–541.
67. O'Toole RV, Joshi M, Carlini AR, et al. Local antibiotic therapy to reduce infection after operative treatment of fractures at high risk of infection: a multicenter, randomized, controlled trial (VANCO study). *J Orthop Trauma*. 2017;31(suppl 1):S18–S24.

68. Cavanaugh DL, Berry J, Yarburo SR, et al. Better prophylaxis against surgical site infection with local as well as systemic antibiotics. An in vivo study. *J Bone Joint Surg Am*. 2009;91:1907–1912.
69. Egol KA, Nauth A, Lee M, et al. Bone grafting: sourcing, timing, strategies, and alternatives. *J Orthop Trauma*. 2015;29(suppl 12):S10–S14.
70. Dawson J, Kiner D, Gardner W II, et al. The reamer-irrigator-aspirator as a device for harvesting bone graft compared with iliac crest bone graft: union rates and complications. *J Orthop Trauma*. 2014;28:584–590.
71. Glotzbecker MP, Riedel MD, Vitale MG, et al. What's the evidence? Systematic literature review of risk factors and preventive strategies for surgical site infection following pediatric spine surgery. *J Pediatr Orthop*. 2013;33:479–487.
72. Morelli I, Drago L, George DA, et al. Masquelet technique: myth or reality? A systematic review and meta-analysis. *Injury*. 2016;47(suppl 6):S68–S76.
73. Wang X, Luo F, Huang K, et al. Induced membrane technique for the treatment of bone defects due to post-traumatic osteomyelitis. *Bone Joint Res*. 2016;5:101–105.
74. Scholz AO, Gehrman S, Glombitza M, et al. Reconstruction of septic diaphyseal bone defects with the induced membrane technique. *Injury*. 2015;46(suppl 4):S121–S124.
75. Moghaddam A, Zietzschmann S, Bruckner T, et al. Treatment of atrophic tibia non-unions according to 'diamond concept': results of one- and two-step treatment. *Injury*. 2015;46(suppl 4):S39–S50.
76. Wong TM, Lau TW, Li X, et al. Masquelet technique for treatment of posttraumatic bone defects. *ScientificWorldJournal*. 2014;2014:710302.
77. Shiels SM, Raut VP, Patterson PB, et al. Antibiotic-loaded bone graft for reduction of surgical site infection in spinal fusion. *Spine J*. 2017;17:1917–1925.
78. Haimoto S, Schär RT, Nishimura Y, et al. Reduction in surgical site infection with suprafascial intrawound application of vancomycin powder in instrumented posterior spinal fusion: a retrospective case-control study. *J Neurosurg Spine*. 2018;29:193–198.
79. Karargyris O, Polyzois VD, Karabinas P, et al. Papineau debridement, Ilizarov bone transport, and negative-pressure wound closure for septic bone defects of the tibia. *Eur J Orthop Surg Traumatol*. 2014;24:1013–1017.
80. Papineau LJ. Excision-graft with deliberately delayed closing in chronic osteomyelitis [in French]. *Nouv Presse Med*. 1973;2:2753–2755.
81. Seebach E, Holschbach J, Buchta N, et al. Mesenchymal stromal cell implantation for stimulation of long bone healing aggravates Staphylococcus aureus induced osteomyelitis. *Acta Biomater*. 2015;21:165–177.
82. Patzakis MJ, Zalavras CG. Chronic posttraumatic osteomyelitis and infected nonunion of the tibia: current management concepts. *J Am Acad Orthop Surg*. 2005;13:417–427.
83. Lindsey RW, Probe R, Miclau T, et al. The effects of antibiotic-impregnated autogenic cancellous bone graft on bone healing. *Clin Orthop Relat Res*. 1993;291:303–312.
84. Chan YS, Ueng SW, Wang CJ, et al. Antibiotic-impregnated autogenic cancellous bone grafting is an effective and safe method for the management of small infected tibial defects: a comparison study. *J Trauma*. 2000;48:246–255.
85. Chen CE, Ko JY, Pan CC. Results of vancomycin-impregnated cancellous bone grafting for infected tibial nonunion. *Arch Orthop Trauma Surg*. 2005;125:369–375.
86. Atique FB, Khalil MM. The bacterial contamination of allogeneic bone and emergence of multidrug-resistant bacteria in tissue bank. *Biomed Res Int*. 2014;2014:430581.
87. Aponte-Tinao LA, Ayerza MA, Muscolo DL, et al. What are the risk factors and management options for infection after reconstruction with massive bone allografts? *Clin Orthop Relat Res*. 2016;474:669–673.
88. Winkler H, Haiden P. Allograft bone as antibiotic carrier. *J Bone Joint Infect*. 2017;2:52–62.
89. Dastgheyb SS, Toorkey CB, Shapiro IM, et al. Porphyrin-adsorbed allograft bone: a photoactive, antibiofilm surface. *Clin Orthop Relat Res*. 2015;473:2865–2873.
90. Barckman J, Baas J, Sorensen M, et al. Does tobramycin impregnation of allograft bone affect implant fixation?—an experimental study in 12 dogs. *J Biomed Mater Res B Appl Biomater*. 2014;102:173–180.
91. Coraca-Huber DC, Ammann CG, Nogler M, et al. Lyophilized allogeneic bone tissue as an antibiotic carrier. *Cell Tissue Bank*. 2016;17:629–642.
92. Anagnostakos K, Koch K. Pharmacokinetic properties and systemic safety of vancomycin-impregnated cancellous bone grafts in the treatment of spondylodiscitis. *Biomed Res Int*. 2013;2013:358217.
93. Ketonis C, Barr S, Shapiro IM, et al. Antibacterial activity of bone allografts: comparison of a new vancomycin-tethered allograft with allograft loaded with adsorbed vancomycin. *Bone*. 2011;48:631–638.
94. Almodóvar J, Mower J, Banerjee A, et al. Chitosan-heparin polyelectrolyte multilayers on cortical bone: periosteum-mimetic, cytophilic, antibacterial coatings. *Biotechnol Bioeng*. 2013;110:609–618.
95. Winkler H, Kaudela K, Stoiber A, et al. Bone grafts impregnated with antibiotics as a tool for treating infected implants in orthopedic surgery - one stage revision results. *Cell Tissue Bank*. 2006;7:319–323.
96. Barger J, Fragomen AT, Rozbruch SR. Antibiotic-coated interlocking intramedullary nail for the treatment of long-bone osteomyelitis. *JBJS Rev*. 2017;5:e5.
97. Thonse R, Conway JD. Antibiotic cement-coated nails for the treatment of infected nonunions and segmental bone defects. *J Bone Joint Surg Am*. 2008;90(suppl 4):163–174.
98. Penner MJ, Duncan CP, Masri BA. The in vitro elution characteristics of antibiotic-loaded CMW and Palacos-R bone cements. *J Arthroplasty*. 1999;14:209–214.
99. Penalba Arias P, Furustrand Taffin U, Betrisey B, et al. Activity of bone cement loaded with daptomycin alone or in combination with gentamicin or PEG600 against Staphylococcus epidermidis biofilms. *Injury*. 2015;46:249–253.
100. Kuechle DK, Landon GC, Musher DM, et al. Elution of vancomycin, daptomycin, and amikacin from acrylic bone cement. *Clin Orthop Relat Res*. 1991;264:302–308.
101. Grimsrud C, Raven R, Fothergill AW, et al. The in vitro elution characteristics of antifungal-loaded PMMA bone cement and calcium sulfate bone substitute. *Orthopedics*. 2011;34:e378–e381.
102. Walenkamp GH, Kleijn LL, de Leeuw M. Osteomyelitis treated with gentamicin-PMMA beads: 100 patients followed for 1-12 years. *Acta Orthop Scand*. 1998;69:518–522.
103. Morgenstern M, Vallejo A, McNally MA, et al. The effect of local antibiotic prophylaxis when treating open limb fractures: a systematic review and meta-analysis. *Bone Joint Res*. 2018;7:447–456.
104. Decoster TA, Bozorgnia S. Antibiotic beads. *J Am Acad Orthop Surg*. 2008;16:674–678.
105. Wasko MK, Kaminski R. Custom-made antibiotic cement nails in orthopaedic trauma: review of outcomes, new approaches, and perspectives. *Biomed Res Int*. 2015;2015:387186.
106. Kanakaris N, Gudipati S, Tosounidis T, et al. The treatment of intramedullary osteomyelitis of the femur and tibia using the Reamer-Irrigator-Aspirator system and antibiotic cement rods. *Bone Joint J*. 2014;96-B:783–788.
107. Yu X, Wu H, Li J, et al. Antibiotic cement-coated locking plate as a temporary internal fixator for femoral osteomyelitis defects. *Int Orthop*. 2017;41:1851–1857.
108. Schmidmaier G, Kerstan M, Schwabe P, et al. Clinical experiences in the use of a gentamicin-coated titanium nail in tibia fractures. *Injury*. 2017;48:2235–2241.
109. Reilly RM, Robertson T, O'Toole RV, et al. Are antibiotic nails effective in the treatment of infected tibial fractures? *Injury*. 2016;47:2809–2815.
110. Wasko MK, Borens O. Antibiotic cement nail for the treatment of post-traumatic intramedullary infections of the tibia: midterm results in 10 cases. *Injury*. 2013;44:1057–1060.
111. Conway J, Mansour J, Kotze K, et al. Antibiotic cement-coated rods: an effective treatment for infected long bones and prosthetic joint nonunions. *Bone Joint J*. 2014;96-B:1349–1354.
112. Pawar A, Dikmen G, Fragomen A, et al. Antibiotic-coated nail for fusion of infected charcot ankles. *Foot Ankle Int*. 2013;34:80–84.
113. Greene N, Holtom PD, Warren CA, et al. In vitro elution of tobramycin and vancomycin polymethylmethacrylate beads and spacers from Simplex and Palacos. *Am J Orthop*. 1998;27:201–205.
114. Chang YH, Tai CL, Hsu HY, et al. Liquid antibiotics in bone cement: an effective way to improve the efficiency of antibiotic release in antibiotic loaded bone cement. *Bone Joint Res*. 2014;3:246–251.
115. Barth RE, Vogely HC, Hoepelman AI, et al. "To bead or not to bead?" Treatment of osteomyelitis and prosthetic joint-associated infections

- with gentamicin bead chains. *Int J Antimicrob Agents*. 2011;38:371–375.
116. van de Belt H, Neut D, Uges DR, et al. Surface roughness, porosity and wettability of gentamicin-loaded bone cements and their antibiotic release. *Biomaterials*. 2000;21:1981–1987.
 117. Neut D, van de Belt H, Stokroos I, et al. Biomaterial-associated infection of gentamicin-loaded PMMA beads in orthopaedic revision surgery. *J Antimicrob Chemother*. 2001;47:885–891.
 118. Webb ND, McCanless JD, Courtney HS, et al. Daptomycin eluted from calcium sulfate appears effective against *Staphylococcus*. *Clin Orthop Relat Res*. 2008;466:1383–1387.
 119. Howlin RP, Brayford MJ, Webb JS, et al. Antibiotic-loaded synthetic calcium sulfate beads for prevention of bacterial colonization and biofilm formation in periprosthetic infections. *Antimicrob Agents Chemother*. 2015;59:111–120.
 120. McKee MD, Li-Bland EA, Wild LM, et al. A prospective, randomized clinical trial comparing an antibiotic-impregnated bioabsorbable bone substitute with standard antibiotic-impregnated cement beads in the treatment of chronic osteomyelitis and infected nonunion. *J Orthop Trauma*. 2010;24:483–490.
 121. Gitelis S, Brebach GT. The treatment of chronic osteomyelitis with a biodegradable antibiotic-impregnated implant. *J Orthop Surg (Hong Kong)*. 2002;10:53–60.
 122. Chang W, Colangeli M, Colangeli S, et al. Adult osteomyelitis: debridement versus debridement plus Osteoset T pellets. *Acta Orthop Belg*. 2007;73:238–243.
 123. Humm G, Noor S, Bridgeman P, et al. Adjuvant treatment of chronic osteomyelitis of the tibia following exogenous trauma using OSTEOSET(R)-T: a review of 21 patients in a regional trauma centre. *Strateg Trauma Limb Reconstr*. 2014;9:157–161.
 124. Ferguson JY, Dudareva M, Riley ND, et al. The use of a biodegradable antibiotic-loaded calcium sulphate carrier containing tobramycin for the treatment of chronic osteomyelitis: a series of 195 cases. *Bone Joint J*. 2014;96-B:829–836.
 125. McNally M, Ferguson J, Kendall J, et al. A comparative study of three bioabsorbable antibiotic carriers in chronic osteomyelitis: 313 patients with minimum one-year follow-up. *Bone Joint J Orthop Proc*. 2015;97-B.
 126. McNally M, Ferguson J, Mifsud M, et al. Internal fixation and local antibiotics for infected nonunions: technique and outcome at over one year. *Bone Joint J Orthop Proc*. 2018;100-B(suppl 8).
 127. Rahaman MN, Day DE, Bal BS, et al. Bioactive glass in tissue engineering. *Acta Biomater*. 2011;7:2355–2373.
 128. Kaur G, Pandey OP, Singh K, et al. A review of bioactive glasses: their structure, properties, fabrication and apatite formation. *J Biomed Mater Res A*. 2014;102:254–274.
 129. Lindfors N, Geurts J, Drago L, et al. Antibacterial bioactive glass, S53P4, for chronic bone infections—a multinational study. *Adv Exp Med Biol*. 2017;971:81–92.
 130. Coraca-Huber DC, Fille M, Hausdorfer J, et al. Efficacy of antibacterial bioactive glass S53P4 against *S. aureus* biofilms grown on titanium discs in vitro. *J Orthop Res*. 2014;32:175–177.
 131. Cunha MT, Murça MA, Nigro S, et al. In vitro antibacterial activity of bioactive glass S53P4 on multiresistant pathogens causing osteomyelitis and prosthetic joint infection. *BMC Infect Dis*. 2018;18:157.
 132. Lindfors NC, Hyvönen P, Nyssönen M, et al. Bioactive glass S53P4 as bone graft substitute in treatment of osteomyelitis. *Bone*. 2010;47:212–218.
 133. Geurts J, Vranken T, Gabriels F, et al. Contemporary treatment of chronic osteomyelitis: implementation in low- and middle-income countries. *South Afr Orthopaedic J*. 2018;17:40–43.
 134. Metsemakers WJ, Moriarty TF, Nijs S, et al. Influence of implant properties and local delivery systems on the outcome in operative fracture care. *Injury*. 2016;47:595–604.
 135. Fuchs T, Stange R, Schmidmaier G, et al. The use of gentamicin-coated nails in the tibia: preliminary results of a prospective study. *Arch Orthop Trauma Surg*. 2011;131:1419–1425.
 136. Metsemakers WJ, Reul M, Nijs S. The use of gentamicin-coated nails in complex open tibia fracture and revision cases: a retrospective analysis of a single center case series and review of the literature. *Injury*. 2015;46:2433–2437.
 137. Ruszczak Z, Friess W. Collagen as a carrier for on-site delivery of antibacterial drugs. *Adv Drug Deliv Rev*. 2003;55:1679–1698.
 138. Wernet E, Ekkernkamp A, Jellestad H, et al. Antibiotic-containing collagen sponge in therapy of osteitis [in German]. *Unfallchirurg*. 1992;95:259–264.
 139. Chaudhary S, Sen RK, Saini UC, et al. Use of gentamicin-loaded collagen sponge in internal fixation of open fractures. *Chin J Traumatol*. 2011;14:209–214.
 140. Knaepler H. Local application of gentamicin-containing collagen implant in the prophylaxis and treatment of surgical site infection in orthopaedic surgery. *Int J Surg*. 2012;10(suppl 1):S15–S20.
 141. Bennett-Guerrero E, Ferguson TB Jr, Lin M, et al. Effect of an implantable gentamicin-collagen sponge on sternal wound infections following cardiac surgery: a randomized trial. *JAMA*. 2010;304:755–762.
 142. Stemberger A, Grimm H, Bader F, et al. Local treatment of bone and soft tissue infections with the collagen-gentamicin sponge. *Eur J Surg Suppl*. 1997;578:17–26.
 143. Walz M. Use of a collagen-gentamicin compound in open spongiosa-plasty in chronic post-traumatic osteomyelitis [in German]. *Aktuelle Probl Chir Orthop*. 1990;34:104–106.
 144. ter Boo GJ, Grijpma DW, Moriarty TF, et al. Antimicrobial delivery systems for local infection prophylaxis in orthopedic- and trauma surgery. *Biomaterials*. 2015;52:113–125.
 145. Giavaresi G, Meani E, Sartori M, et al. Efficacy of antibacterial-loaded coating in an in vivo model of acutely highly contaminated implant. *Int Orthop*. 2014;38:1505–1512.
 146. Boot W, Gawlitta D, Nikkels PGJ, et al. Hyaluronic acid-based hydrogel coating does not affect bone apposition at the implant surface in a rabbit model. *Clin Orthop Relat Res*. 2017;475:1911–1919.
 147. Malizos K, Blauth M, Danita A, et al. Fast-resorbable antibiotic-loaded hydrogel coating to reduce post-surgical infection after internal osteosynthesis: a multicenter randomized controlled trial. *J Orthop Traumatol*. 2017;18:159–169.
 148. Moriarty TF, Kuehl R, Coenye T, et al. Orthopaedic device-related infection: current and future interventions for improved prevention and treatment. *EFORT Open Rev*. 2016;1:89–99.
 149. Alexander JW. History of the medical use of silver. *Surg Infect (Larchmt)*. 2009;10:289–292.
 150. Fromm KM. Bioinorganic chemistry of silver: its interactions with amino acids and peptides. *Chim (Aarau)*. 2013;67:851–854.
 151. Brennan SA, Ní Fhoghlú C, Devitt BM, et al. Silver nanoparticles and their orthopaedic applications. *Bone Joint J*. 2015;97-B:582–589.
 152. Maillard JY, Hartemann P. Silver as an antimicrobial: facts and gaps in knowledge. *Crit Rev Microbiol*. 2013;39:373–383.
 153. Siegel HJ, Herrera DF, Gay J. Silver negative pressure dressing with vacuum-assisted closure of massive pelvic and extremity wounds. *Clin Orthop Relat Res*. 2014;472:830–835.
 154. Rupp ME, Lisco SJ, Lipsett PA, et al. Effect of a second-generation venous catheter impregnated with chlorhexidine and silver sulfadiazine on central catheter-related infections: a randomized, controlled trial. *Ann Intern Med*. 2005;143:570–580.
 155. Saint S, Elmore JG, Sullivan SD, et al. The efficacy of silver alloy-coated urinary catheters in preventing urinary tract infection: a meta-analysis. *Am J Med*. 1998;105:236–241.
 156. Kollef MH, Afessa B, Anzueto A, et al. Silver-coated endotracheal tubes and incidence of ventilator-associated pneumonia: the NASCENT randomized trial. *JAMA*. 2008;300:805–813.
 157. Glehr M, Leithner A, Friesenbichler J, et al. Argyria following the use of silver-coated megaprotheses: no association between the development of local argyria and elevated silver levels. *Bone Joint J*. 2013;95-B:988–992.
 158. Schmolders J, Koob S, Schepers P, et al. Lower limb reconstruction in tumor patients using modular silver-coated megaprotheses with regard to perimegaprosthesis joint infection: a case series, including 100 patients and review of the literature. *Arch Orthop Trauma Surg*. 2017;137:149–153.
 159. Massè A, Bruno A, Bosetti M, et al. Prevention of pin track infection in external fixation with silver coated pins: clinical and microbiological results. *J Biomed Mater Res*. 2000;53:600–604.
 160. Kutateladze M, Adamia R. Bacteriophages as potential new therapeutics to replace or supplement antibiotics. *Trends Biotechnol*. 2010;28:591–595.
 161. Akanda ZZ, Taha M, Abdelbary H. Current review-The rise of bacteriophage as a unique therapeutic platform in treating peri-prosthetic joint infections. *J Orthop Res*. 2018;36:1051–1060.

162. Alisky J, Iczkowski K, Rapoport A, et al. Bacteriophages show promise as antimicrobial agents. *J Infect.* 1998;36:5–15.
163. Morozova VV, Vlassov VV, Tikunova NV. Applications of bacteriophages in the treatment of localized infections in humans. *Front Microbiol.* 2018;9:1696.
164. Yilmaz C, Colak M, Yilmaz BC, et al. Bacteriophage therapy in implant-related infections: an experimental study. *J Bone Joint Surg Am.* 2013;95:117–125.
165. Ferry T, Leboucher G, Fevre C, et al. Salvage debridement, antibiotics and implant retention (“DAIR”) with local injection of a selected cocktail of bacteriophages: is it an option for an elderly patient with relapsing *Staphylococcus aureus* prosthetic-joint infection? *Open Forum Infect Dis.* 2018;5:ofy269.
166. Vandenneuvel D, Lavigne R, Brüßow H. Bacteriophage therapy: advances in formulation strategies and human clinical trials. *Annu Rev Virol.* 2015;2:599–618.
167. Malik DJ, Sokolov IJ, Vinner GK, et al. Formulation, stabilisation and encapsulation of bacteriophage for phage therapy. *Adv Colloid Interf Sci.* 2017;249:100–133.